

Journal: *Journal of Spine Surgery*

Manuscript ID: JSS-19-83

doi: 10.21037/jss.2019.06.07

Title: Expandable spacers provide better functional outcomes than static spacers in minimally invasive transforaminal lumbar interbody fusion

Corresponding author: M. Adam Kremer

Dear Dr. Kremer,

The proof of your manuscript is attached on the following pages. Please read through the document carefully to check the text, tables and references for accuracy. Please also be aware that a professional copyeditor may have edited your manuscript to comply with the JSS style requirements.

In addition to proofing the article, the following queries have arisen during the preparation of your paper. Please address the queries listed below by making the appropriate changes in the text.

If you have any other revisions that you would like to make, this will be the last opportunity to do so before the article is published. In particular, please ensure that the author's names and affiliations have been identified correctly, and the address of the corresponding author is correct.

If the changes cannot be easily described through email, please annotate this proof according to the annotation guidelines as detailed on the following page.

Query Reference	Query	Author's response
Q1	Please note that alterations cannot be made after you have approved for publication, irrespective of whether it is Online First.	
Q2	Author SURNAMES (family names) have been highlighted in red - please check that these are correct.	
Q3	Please check affiliations, correspondence details.	
Q4	Please check acknowledgements section and confirm the conflict.	
Q5	Please note that the link with the doi number for the manuscript should be valid only after the whole issue is officially published.	
Q6	Please supplement the vacant information in the Contributions section.	
Q7	Confirm that the authors are accountable for all aspects of the work (if applied, including full data access, integrity of the data and the accuracy of the data analysis) in ensuring that questions related to the accuracy or integrity of any part of the work are appropriately investigated and resolved. Please note that the above statement must be included in the footnote of the article as part of the Ethical Statement.	

Once you have completed your revisions and/or addressed all the queries, or if you are satisfied with the proof in its existing form, please email: e-proof@amegroups.com.

**To ensure the timely publication of your article, please respond within 48 hours.**

## Making corrections

Use Adobe Reader – available for free from <http://get.adobe.com/reader/> – to open the attached document.

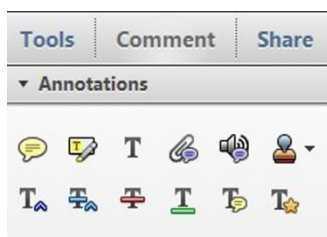


Figure 1 Adobe Acrobat X

Adobe Professional 7:





*Tools* → *Commenting* → *show Commenting Toolbar*

Adobe Reader 8:

*Tools* → *Comments & Markup* → *show Comments and Markup Toolbar*

Adobe Reader 10 and above:

*Comment* → *choose either Sticky Note or Highlight Text*

<p><b>In-text edits</b></p>	<p><b>Select the appropriate symbol and then click and drag over the text to be modified.</b></p> <p><b>Replace</b> : denotes where the text should be replaced with an alternative option</p> <p><b>Strikethrough</b> : crosses out the text</p> <p><b>Underline</b> : underlines the text</p> <p><b>Add note to text</b> : links selected text with a pop-up note</p>
<p><b>Sticky notes</b></p>	<p><b>To make a note:</b> choose the Sticky Note option and then click on a desired location</p> <p><b>Changing the name:</b> double-click and choose Options → Sticky Note Properties → General → insert desired name</p> <p><b>To move:</b> click anywhere (apart from the text field) and drag</p> <p><b>To resize:</b> click on the right or left hand order and drag</p> <p><b>To close:</b> click the box on the upper right corner; this does NOT delete your note</p> <p><b>To delete:</b> click and press the Delete keyboard button or right click and select delete from the drop-down menu</p>
<p><b>Highlighting</b></p>	<p><b>This allows you can highlight parts of the text.</b></p> <p><b>To highlight:</b> select Highlight and then click and drag over the text to be highlighted. When finished, click on Highlight again to turn off the option.</p> <p><b>To change the colour:</b> double-click on the highlighted text and choose Options → Properties → Appearance → Color</p>

Saving your changes:

Click on *File* → *Save* before closing the document.

For more detailed instructions on using Adobe Acrobat, please refer to <http://www.adobe.com/support/acrobat/gettingstarted/>

# Expandable spacers provide better functional outcomes than static spacers in minimally invasive transforaminal lumbar interbody fusion

M. Adam Kremer<sup>1</sup>, Jefferson Alferink<sup>1</sup>, Stacie Wynsma<sup>1</sup>, Torrey Shirk<sup>2</sup>, Charles Ledonio<sup>2</sup>

<sup>1</sup>The Brain and Spine Center, Holland, MI, USA; <sup>2</sup>Globus Medical, Inc., Audubon, PA, USA

**Contributions:** (I) Conception and design: XXX; (II) Administrative support: XXX; (III) Provision of study materials or patients: XXX; (IV) Collection and assembly of data: XXX; (V) Data analysis and interpretation: XXX; (VI) Manuscript writing: All authors; (VII) Final approval of manuscript: All authors.

**Correspondence to:** M. Adam Kremer, MD. 3299 N Wellness Dr #240, Holland, MI 49424, USA. Email: adam.kremer@brain-and-spine.com.

**Background:** Transforaminal lumbar interbody fusion is an effective and frequently performed surgical treatment of chronic lower back pain. Expandable interbody spacers are designed to create greater disc height through *in situ* expansion. It remains unclear whether the benefits of expandable technology will translate into clinical benefits. The current study compares expandable to static interbody spacers.

**Methods:** This is a retrospective study of 99 patients (48 static and 51 expandable) at a single site. Radiographs were collected preoperatively and at 3 months postoperatively. Standard of care at this site requires radiographs to be taken past 3 months only if patients are suffering from a severe recurrence of symptoms. Patient reported outcomes, Oswestry disability index (ODI) and visual analog scale (VAS), were collected preoperatively, at 1 and 3 months postoperatively. Patients were contacted by the surgeon and patient reported outcomes were collected at a final time point. Average final follow-up for was 67.1±16.3 months and for expandable patients it was 43.0±4.2 months.

**Results:** At 3 months postoperatively and at final follow-up, patients treated with expandable interbody spacers had significantly lower average ODI scores than patients with static interbody spacers. Both groups reported significant reductions in VAS scores through all follow-up. At 4 years postoperative 8 static group patients and 3 expandable group patients returned for recurrence of symptoms.

**Conclusions:** Expandable interbody spacers in this study were found to be comparable to static interbody spacers, with improvements in VAS and ODI scores.

**Keywords:** Intervertebral disc degeneration; spinal fusion; low back pain

Submitted Mar 01, 2019. Accepted for publication May 31, 2019.

doi: 10.21037/jss.2019.06.07

View this article at: <http://dx.doi.org/10.21037/jss.2019.06.07>

## Introduction

Transforaminal lumbar interbody fusion (TLIF) has been shown to be an effective surgical procedure for spondylolisthesis and related spinal disorders requiring surgical intervention (1-4). A critical component to the success of TLIF is the interbody spacer, which can help achieve sagittal correction. Since the preservation or restoration of sagittal alignment is a significant predictor in

determining patient outcomes (5-7), increasing disc height, improving segmental lordosis, and achieving adequate indirect decompression are of the utmost importance.

Static interbody spacers have traditionally been used for spinal arthrodesis (8,9). Favorable outcomes have been reported following their use in anterior, posterior, and TLIF procedures (10-13). Most clinical outcome studies documented in the literature have focused on static interbody spacers, but

expandable devices have recently become available.

Expandable spacers have been designed to be inserted at a minimized profile and expanded *in situ* for decreased trialing and iatrogenic endplate disruption secondary to impaction, in comparison to static devices. The potential surgical advantages of expandable devices include less neural retraction, decreased endplate damage, and less implant subsidence and/or migration. Functional clinical studies have provided evidence on the effectiveness of these new devices in improving patient outcomes compared to traditional devices. The objective of this study is to compare the clinical functional outcomes in patients treated with expandable spacers to those of static spacers in minimally invasive (MIS) TLIF.

## Methods

Institutional Review Board approval was received and the patients were contacted by the principal investigator (PI) (ID: 1172515). Informed consent was given by all patients allowing the review of their data. A review was performed on the medical records of 99 patients who underwent TLIF, with 48 patients having been treated with a static and 51 having been treated with an expandable interbody spacer.

### Outcome measures

Patient-reported clinical outcomes, visual analog scale (VAS) pain scores and Oswestry Disability Index (ODI), were collected from patient records, and subjects were contacted for final follow-up. Average final follow-up was  $67.1 \pm 16.3$  months for static patients and  $43.0 \pm 4.2$  months for expandable patients, for an overall average final follow-up of  $54.7 \pm 16.9$  months for all patients. All of the expandable interbody group patients completed patient reported outcomes through final follow-up, while 38 of 48 static interbody group patients completed patient reported outcomes through final follow-up. Radiographs were collected from the record system when available. Standard of care at the institution was for radiographs to be taken after 3 months only if the PI believed they were medically necessary, in order to reduce radiation exposure to patients. Therefore, radiographs were not collected for all patients at all time points.

### Statistical analysis

Data were statistically analyzed using SPSS version 20.0.0

software for Windows (IBM Corp., Armonk, New York, USA). Frequency tables, descriptive statistics, and measures of central tendencies were calculated. Paired samples *t*-tests were used to compare outcomes over time, with *P* values of less than 0.05 considered significant. Independent sample *t*-tests were used to compare treatment groups, with the same significance threshold of 0.05.

### Surgical technique

After general anesthesia, patients were positioned prone and secured on the operating table with adequate padding. A short 2–3-inch incision was made over the operative spinal level. Soft tissues were dissected down to bone in a MIS fashion. Tube retractors were placed, and facet joints and pars interarticularis were visualized. Percutaneous headless pedicle screws were placed bilaterally under C-arm fluoroscopy. This was followed by facetectomy under a microscope from an oblique approach (i.e., transforaminal), sometimes adding table rotation and angulating the tube medially to perform bilateral facetectomies if bilateral decompression was necessary. Next discectomy was performed and endplates were prepared. For patients receiving treatment with a static interbody spacer, repeated trials were used for sizing and preparation. For patients receiving treatment with expandable interbody spacers, trialing for implant height was not necessary as the height of the implant is adjusted *in situ*. The interbody spacer was filled with either cellular bone matrix or bone morphogenetic protein (BMP) and placement was completed via Kambin's triangle. The rods were then passed bilaterally and set screws were secured. Pedicle screw and spacer placement was checked using fluoroscopy. Skin was washed and closed with sutures and skin glue in standard fashion. Patients were discharged either on the same day or 24 hours later.

## Results

Indications for surgery included degenerative spondylolisthesis, spinal stenosis with or without recurrent herniated nucleus pulposus and degenerative disc disease. A breakdown of indications is displayed in *Table 1*. Of the total 99 patients, 48.5 percent were female, and there was no significant difference in gender proportions between study groups. There was no significant difference in age at surgery between the two study groups, with an average age of 61 years for all patients (*Table 2*). Patients treated with

expandable interbody spacers had significantly less blood loss (81.7 *vs.* 36.2 mL,  $P<0.001$ ) and shorter hospital stays (2.2 *vs.* 1.4 days) than patients treated with static interbody spacers. Operating room time for patients treated with expandable interbody spacers was 130.6 ( $\pm 55.2$ ) minutes, compared to 149.5 ( $\pm 44.3$ ) minutes for patients treated with static spacers. Despite a difference of 18.9 minutes on average, the difference did not reach significance ( $P=0.074$ ).

At 3-month follow-up, patients treated with expandable interbody spacers had significantly lower average ODI

scores than patients with static interbody spacers ( $P<0.001$ , *Table 3*). At final follow-up, patients treated with expandable interbody spacers continued to show significantly lower average ODI scores than patients treated with static interbody spacers ( $P=0.016$ ).

In the static cohort, there was one instance of deep vein thrombosis, one instance of vertigo, two instances of low blood pressure, one instance of wound infection, one instance of post-fall leg weakness, and one instance of hypoglycemia. In the expandable cohort, the only reported complication was an emergency room knee aspiration.

Disc height and neuroforaminal height increased significantly ( $P<0.05$ ) from baseline at the 3-month follow-up time point for both interbody spacers. The expandable group had significantly greater neuroforaminal height (22.3 *vs.* 20.1 mm) than the static group ( $P<0.05$ ).

The standard of care for patients at the study site did not require radiographs to be taken past 3-month postoperative follow-up unless the patient reported a recurrence of severe low back pain or other symptoms. Only 3 of 51 (6%) patients from the expandable group had to have imaging taken at  $>24$  months, compared to 12 of 48 (25%) patients in the static group, which was significant ( $P<0.05$ ). The

**Table 1** Indications for surgery

Surgical indication	Expandable	Static
Degenerative spondylolisthesis w/o HNP	25	13
Stenosis w/o HNP	11	21
DDD w/o radiculopathy	14	12
Radiculopathy	0	2
Adult degenerative scoliosis with stenosis	1	0

w/o, with or without; HNP, herniated nucleus pulposus; DDD, degenerative disc disease.

**Table 2** Operative data

Data category	Age at surgery (years)	OR time (min)	Blood loss (mL)	LOS (days)
Static	58.3 $\pm$ 13.7	149.5 $\pm$ 44.3	81.7 $\pm$ 82.8	2.2 $\pm$ 1.4
Expandable	62.8 $\pm$ 13.5	130.6 $\pm$ 55.2	36.2 $\pm$ 26.0	1.4 $\pm$ 0.4
Independent t-test P value	0.106	0.074	$<0.001^*$	$<0.001^*$

\*, indicates significance. OR, operating room; LOS, length of stay.

**Table 3** Patient reported outcomes

Data category	Preop	1 m	3 m	Final <sup>†</sup>	Preop to final P value
Static					
ODI (%)	57.0 $\pm$ 17.4	33.3 $\pm$ 16.7	29.1 $\pm$ 21.0	22.6 $\pm$ 16.6	$<0.001^*$
VAS back	6.0 $\pm$ 3.2	2.8 $\pm$ 2.0	2.9 $\pm$ 2.4	2.2 $\pm$ 2.0	$<0.001^*$
VAS leg	7.2 $\pm$ 2.6	2.9 $\pm$ 2.6	2.3 $\pm$ 2.5	1.9 $\pm$ 1.8	$<0.001^*$
Expandable					
ODI (%)	44.4 $\pm$ 11.9	32.6 $\pm$ 18.8	13.0 $\pm$ 11.7	14.4 $\pm$ 13.7	$<0.001^*$
VAS back	6.2 $\pm$ 2.5	3.0 $\pm$ 2.3	2.7 $\pm$ 2.1	2.3 $\pm$ 1.9	$<0.001^*$
VAS leg	6.2 $\pm$ 3.0	2.3 $\pm$ 2.4	1.6 $\pm$ 1.8	2.2 $\pm$ 2.4	$<0.001^*$

<sup>†</sup>, final follow-up for static group: 67.1 $\pm$ 16.3 expandable group: 43.0 $\pm$ 4.2; \*, indicates significance. ODI, Oswestry Disability Index; VAS, visual analog scale.

three patients with a recurrence of pain in the expandable group each returned within 4 years postoperative. Ten of the 12 patients with a recurrence of pain in the static group returned within 4 years postoperative. Furthermore, 4 of the 12 static patients required additional surgery, while the three expandable group patients received only conservative treatment.

## Discussion

This study illustrates favorable radiographic and functional outcomes after MIS TLIF using either expandable or static interbody spacers. Most TLIF-oriented studies focus on radiographic outcomes. However, patient-reported outcome measures are recognized (such as ODI and VAS pain scores) as the most appropriate instruments to assess the effectiveness of healthcare interventions from the patient's perspective, and are sometimes used as metrics for healthcare delivery performance (14,15).

A small number of recent studies have evaluated disc and neuroforaminal heights in patients with expandable interbody devices. Kim *et al.* (16) assessed the radiographic outcomes in 50 patients and reported that MIS TLIF with an expandable interbody device led to a long-lasting increase in disc height, but only a transient increase in foraminal height. Similar to Kim *et al.*, the current study demonstrated that MIS TLIF with an expandable interbody device increased disc height and neuroforaminal heights by 48.7% on average. MIS TLIF with static interbody devices led to a 36.8% smaller increase in disc height. Regardless of radiographic parameters, a key finding of this study was the improvement of functional outcomes. VAS back scores decreased significantly by 64.5%, and ODI scores decreased significantly by 67.5% in the expandable group compared to the static group, with a decrease of 63.3% and 60.4% in VAS and ODI scores, respectively.

Another key finding of the study is the rate of follow-up between both groups. The standard of care for this site was to minimize radiation exposure by ordering X-rays only if clinically indicated. The most common chief complaint was recurring back and leg pain. Only 6% of patients in the expandable group had recurrence of symptoms in contrast to 25% of patients in the static group at final follow-up. Despite the difference in average follow-up ( $67.1 \pm 16.3$  months for static group patients and  $43.0 \pm 4.2$  months for expandable group patients), the eight static group patients and three expandable group patients returned within 4 years postoperative.

Similar results in functional outcomes were reported in one other study. Hawasli *et al.* (17) compared radiographic and clinical outcomes between expandable and static interbody spacers. A total of 48 MIS TLIFs were performed. The expandable group had a greater and more sustained increase in disc height when compared to the static group. Foraminal height increased with the expandable group but not with the static group. In the expandable group, ODI improved more significantly compared to the static group. Both disc height and segmental lordosis were correlated with improved clinical outcomes in the study (17). The results of Hawasli *et al.* are comparable to the results reported here, and support the effectiveness of expandable interbody spacers generally.

Limitations of this study include a small sample size and limited follow-up X-rays, because they were ordered only if clinically indicated in order to reduce radiation exposure in accordance with the standard of care for this site.

## Conclusions

This study adds to current body of research demonstrating that expandable interbody spacers provide comparable height restoration and clinical outcome scores when compared to static interbody spacers.

## Acknowledgments

None.

## Footnote

*Conflicts of Interest:* The authors have no conflicts of interest to declare.

*Ethical Statement:* Institutional Review Board approval was received and the patients were contacted by the Principal Investigator (PI) (ID: 1172515). Informed consent was given by all patients allowing the review of their data. The authors are accountable for all aspects of the work in ensuring that questions related to the accuracy or integrity of any part of the work are appropriately investigated and resolved.

## References

1. Ghasemi AA. Transforaminal lumbar interbody fusion versus instrumented posterolateral fusion In degenerative

- spondylolisthesis: An attempt to evaluate the superiority of one method over the other. *Clin Neurol Neurosurg* 2016;150:1-5.
2. de Kunder SL, van Kuijk SMJ, Rijkers K, et al. Transforaminal lumbar interbody fusion (TLIF) versus posterior lumbar interbody fusion (PLIF) in lumbar spondylolisthesis: a systematic review and meta-analysis. *Spine J* 2017;17:1712-21.
  3. Glassman SD, Carreon LY, Ghogawala Z, et al. Benefit of Transforaminal Lumbar Interbody Fusion vs Posterolateral Spinal Fusion in Lumbar Spine Disorders: A Propensity-Matched Analysis From the National Neurosurgical Quality and Outcomes Database Registry. *Neurosurgery* 2016;79:397-405.
  4. Lee N, Kim KN, Yi S, et al. Comparison of Outcomes of Anterior, Posterior, and Transforaminal Lumbar Interbody Fusion Surgery at a Single Lumbar Level with Degenerative Spinal Disease. *World Neurosurg* 2017;101:216-26.
  5. Glassman SD, Bridwell K, Dimar JR, et al. The impact of positive sagittal balance in adult spinal deformity. *Spine (Phila Pa 1976)* 2005;30:2024-9.
  6. Glassman SD, Berven S, Bridwell K, et al. Correlation of radiographic parameters and clinical symptoms in adult scoliosis. *Spine (Phila Pa 1976)* 2005;30:682-8.
  7. Rodgers JA, Gerber EJ, Lehmen JA, et al. Clinical and Radiographic Outcome in Less Invasive Lumbar Fusion: XLIF at Two Year Follow-Up. *J Spine Neurosurg* 2013. doi:10.4172/2325-9701.1000111
  8. Bagby GW. Arthrodesis by the distraction-compression method using a stainless steel implant. *Orthopedics* 1988;11:931-4.
  9. McAfee PC. Interbody fusion cages in reconstructive operations on the spine. *J Bone Joint Surg Am* 1999;81:859-80.
  10. Malham GM, Ellis NJ, Parker RM, et al. Clinical outcome and fusion rates after the first 30 extreme lateral interbody fusions. *ScientificWorldJournal* 2012;2012:246989.
  11. Phillips FM, Isaacs RE, Rodgers WB, et al. Adult degenerative scoliosis treated with XLIF: clinical and radiographical results of a prospective multicenter study with 24-month follow-up. *Spine (Phila Pa 1976)* 2013;38:1853-61.
  12. Sharma AK, Kepler CK, Girardi FP, et al. Lateral lumbar interbody fusion: clinical and radiographic outcomes at 1 year: a preliminary report. *J Spinal Disord Tech* 2011;24:242-50.
  13. Youssef JA, McAfee PC, Patty CA, et al. Minimally invasive surgery: lateral approach interbody fusion: results and review. *Spine (Phila Pa 1976)* 2010;35:S302-11.
  14. Mercieca-Bebber R, King MT, Calvert MJ, Stockler MR, Friedlander M. The importance of patient-reported outcomes in clinical trials and strategies for future optimization. *Patient Relat Outcome Meas* 2018;9:353-67.
  15. Weldring T, Smith SM. Patient-Reported Outcomes (Pros) and Patient-Reported Outcome Measures (Proms). *Health Serv Insights* 2013;6:61-8.
  16. Kim CW, Doerr TM, Luna IY, et al. Minimally Invasive Transforaminal Lumbar Interbody Fusion Using Expandable Technology: A Clinical and Radiographic Analysis of 50 Patients. *World Neurosurg* 2016;90:228-35.
  17. Hawasli AH, Khalifeh JM, Chatrath A, et al. Minimally invasive transforaminal lumbar interbody fusion with expandable versus static interbody devices: radiographic assessment of sagittal segmental and pelvic parameters. *Neurosurg Focus* 2017;43:E10.

**Cite this article as:** Kremer MA, Alferink J, Wynsma S, Shirk T, Ledonio C. Expandable spacers provide better functional outcomes than static spacers in minimally invasive transforaminal lumbar interbody fusion. *J Spine Surg* 2019. doi: 10.21037/jss.2019.06.07